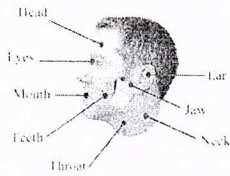


Wilkes stage I – Here the condition is characterized by painless clicking. There is no restricted motion and through imaging a slight forward displacement of the disc can be seen.

Stage II – The condition has progressed to occasional painful clicking. There is intermittent locking of the jaw and headaches. The jaw is displaced and slightly forward. This is the beginning deformity and there is a slight thickening of the posterior edge.



Stage III – Frequent pain is experienced along with joint tenderness, headaches, jaw locking, and restricted motion. It is also painful when chewing. Anterior disc displacement of the jaw with significant deformity or prolapse of disc also appears.

Stage IV – Here the condition has progressed to chronic pain with frequent headaches and restricted motion. This is an increase in severity from previous Stage III with clearly moderate degenerative changes. This is characterized by flattening of the eminence, deformed condylar head, and sclerosis.

Stage V – The most severe stage of TMJ where variable pain, joint crepitus, and painful function prevail. Disc perforation, filling defects, gross anatomic deformity of disc and hard tissues accompanied by degenerative arthritic changes are experienced.